



DATE **CLINICAL BACKGROUND & STUDY DETAILS**

4.6.26

PATIENT

Tori Jedrzejewski

SPECIES

Canine

BREED

Shih Tzu Mix

SEX

FS

AGE

1.15.14

WEIGHT

21lbs

INTERPRETED BY

Maggie Machen Lamy,
DVM, DACVIM
(Cardiology)

HOSPITAL NAME

Northwind AH

REFERRING VET

Dr. Wilson

INVOICE

47430

History: CKD. Tracheal collapse (dx April 2026). Grade II/VI holosystolic murmur newly auscultated ~1 mo prior. History of coughing episodes associated with collapse, concerning for possible syncope. Additional collapse episode reported during recent hospitalization for fluid therapy due to CKD progression (↑ creatinine); patient noted to be significantly stressed (blind, unfamiliar environment). Since discharge, no further collapse episodes. Cough improved with maropitant (off label for tracheal collapse; also used for chronic pancreatitis). PE: BAR. BCS 6/9. Grade II/VI holosystolic murmur. Grade IV periodontal disease. Bilateral mature cataracts. Otherwise unremarkable.

Pertinent abnormal PE/Chem/CBC/UA Results: IRIS Stage III CKD with azotemia (Cr 3.2, BUN 115, SDMA 21), hyperphosphatemia, mild hypercalcemia, electrolyte abnormalities (↑ Na, ↑ K, ↓ Cl, ↓ Na:K, ↑ anion gap. Urine cystatin B elevated.

Current medications: Insulin (Vetsulin): 8.5 units SQ q12h for diabetes mellitus, Maropitant (Cerenia) 16 mg tablets: 1/2 tablet PO SID (off label for tracheal collapse associated cough), Diclofenac ophthalmic solution: topical OU as directed for diabetic cataracts

Sedation used: Not required to complete full diagnostic ultrasound.

Pertinent previous ultrasound results: No previous.

STAT: Not requested.

Imaging performed by: Andi Parkinson RDMS

ECHOCARDIOGRAM FINDINGS

2D, m-mode, color flow and doppler imaging is available. Mild diffuse thickening of mitral valve leaflets with no prolapse into the left atrial lumen. Trace/mild eccentric mitral regurgitation with no left atrial dilation (LA:Ao <1.4). Normal MR velocity. Normal LV diameter with adequate myocardial function. The tricuspid valve appears mildly thickened with no significant tricuspid regurgitation. Normal right atrial and ventricular diameter and morphology indicating no overt evidence of pulmonary arterial hypertension. The pulmonic and aortic valves are normal in morphology and mobility. Normal pulmonic and aortic outflow velocities with laminar flow. No obvious aortic and trace pulmonic insufficiency. No pericardial or pleural effusion noted. No obvious cardiac masses.

CARDIAC CHART

| CANINE CARDIAC PARAMETERS | MR VMAX (m/s) | TR VMAX (m/s) | LA/AO (Boon method) | LA/AO (Heart Base; Swe) | FS (%) | EF (%) | EPSS (cm) |
|---|---------------|---------------|---------------------|-------------------------|---------------------------------|--|--|
| NORMAL PARAMETER | 4.5-5.5 | <2.7 | 1.3 | <1.6 | 28-40 | 40-100 | <0.6 |
| PATIENT | 5.5 | NA | NM | 1.3 | 33 | 65 | NM |
| CANINE CARDIAC PARAMETERS | HR (BPM) | AV VMAX (m/s) | PV MAX (m/s) | BODY WEIGHT (kg) | LA 2D short axis Base view (cm) | LVIDd Avg; 2D and m-mode short axis (cm) | LVIDs Avg; 2D and m-mode short axis (cm) |
| NORMAL PARAMETER | 50-100 | 0.7-1.7 | 0.7-1.6 | BELOW | BELOW | BELOW | BELOW |
| PATIENT | 180 | 1.7 | 0.9 | 9.5 | 1.9 | 2.7 | 1.8 |
| *Normal chamber parameters expressed as a mean value (SD) | | | | 3 | 1.27 (5.3) | 2.46 (2.46) | 1.36 (5.5) |

| BODY WEIGHT DEPENDENT PARAMETERS | 5 | 1.40 (4.5) | 2.74 (5.2) | 1.60 (4.7) |
|---|----|------------|------------|------------|
| <i>*Note: All measurements based upon multi-modal images and methods. An average value is reported.</i> | 10 | 1.50 (3.8) | 3.27 (3.5) | 2.06 (3.1) |
| | 15 | 1.83 (2.0) | 3.71 (2.4) | 2.43 (2.1) |
| | 20 | 2.02 (1.9) | 4.14 (2.2) | 2.80 (2.0) |
| Adapted from June Boon, Veterinary Echocardiography, 1998 | 25 | 2.18 (2.4) | 4.48 (2.9) | 3.10 (2.5) |
| Rishniw M and Hollis NE, J Vet Intern Med 2000; 14:429-435 | 30 | 2.33 (3.3) | 4.83 (3.9) | 3.39 (3.4) |
| Hansson et al, Vet Rad and Ultrasound 2002 | 35 | 2.48 (4.3) | 5.17 (5.0) | 3.69 (4.5) |
| Bonagura et al. Echocardiography: principles of interpretation, Vet Clin North Am 15:1177, 1995 | 40 | 2.62 (5.2) | 5.48 (6.1) | 3.96 (5.4) |
| | 50 | 2.88 (7.1) | 6.07 (8.3) | 4.46 (7.4) |

INTERPRETATION OF THE FINDINGS & FURTHER RECOMMENDATIONS

Chronic degenerative valve disease causing trace/mild mitral regurgitation. Lack of significant left atrial enlargement indicates the current risk for complication is low. No concurrent issues such as systolic dysfunction or pulmonary hypertension are noted in this study. Baseline BP is recommended, given the patient's history.

These findings would suggest the cough/associated cough is unlikely to be cardiac in origin and primary respiratory causes should be considered. Consider further respiratory work up/treatment (hydrocodone, taper course of steroids, Enrofloxacin, TTW/BAL, etc.). A poorly controlled cough can lead to development of pulmonary hypertension over time, and monitoring for associated clinical signs is recommended (primarily exertional syncope/dyspnea).

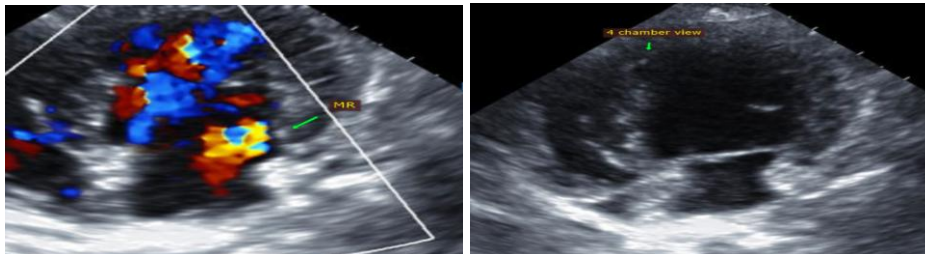
No cardiac medications are clearly indicated, as no benefit has been shown to providing therapy for dogs in stage B1. Omega fatty acid supplementation and mild salt restriction may be of some long-term benefit. Monitor for development of a progressive cough, labored breathing, exercise intolerance or collapse episodes.

Assessment of progression in the future will help predict long term prognosis, which is highly variable with stage B1 disease. Many B1 dogs will remain asymptomatic with slow progression for years to come.

No cardiac contraindication for general anesthesia prior to chamber enlargement.

Recommend conservative monitoring with a recheck echocardiogram in 6-12 months to assess rate of progression, sooner if any development of clinical signs in the interim.

IMAGES



The information and recommendations provided are based on the images presented by the referring veterinarian. No evaluation can be communicated regarding pathology that was not visible in the image/video clips provided.

Thank you for this referral. This report was generated using transcription software, and minor dictation errors may be present. If the clinical or image interpretation does not parallel your findings or if I can be of any further assistance, please contact me.

Maggie Machen Lamy, DVM
Diplomate of the American College of Veterinary Internal Medicine (Cardiology)
info@sonopath.com